



Vertical and horizontal Guided Bone Regeneration (GBR) with resorbable membranes and titanium plates

Rengo Carlo ^{1*}, Teresi Salvatore Emanuele ^{2*}, Vignudelli Elisabetta ², Calamai Paolo ³,
Randellini Emanuele ³, Cucchi Alessandro ²

¹ Department of Prosthodontics and Dental Materials, University of Siena, Siena, Italy. ² Unit of Oral and Maxillofacial Surgery, Department of Biomedical and Neuromotor Science (DIBINEM), University of Bologna, Italy. ³ Unit of Oral & Maxillofacial Surgery, San Leopoldo Mandic University, San Paolo, Brazil.

* Presenter: Carlo Rengo. Mail: carlorenco@alice.it

INTRODUCTION

Many authors demonstrated the predictability of non-resorbable membranes or titanium meshes for bone augmentation for alveolar deficiencies. However, the use of a barrier device is a technique-sensitive procedure and it is not lacking complications. For these reasons, some authors suggested to use only a titanium plate for space-making effect and a resorbable membrane for unwanted-cell exclusion effect. The aim of this study was to evaluate complications and success rates of this kind of GBR, so-called "Fence Technique", in the treatment of vertical and horizontal bone defects after a 1- to 3-years follow-up.

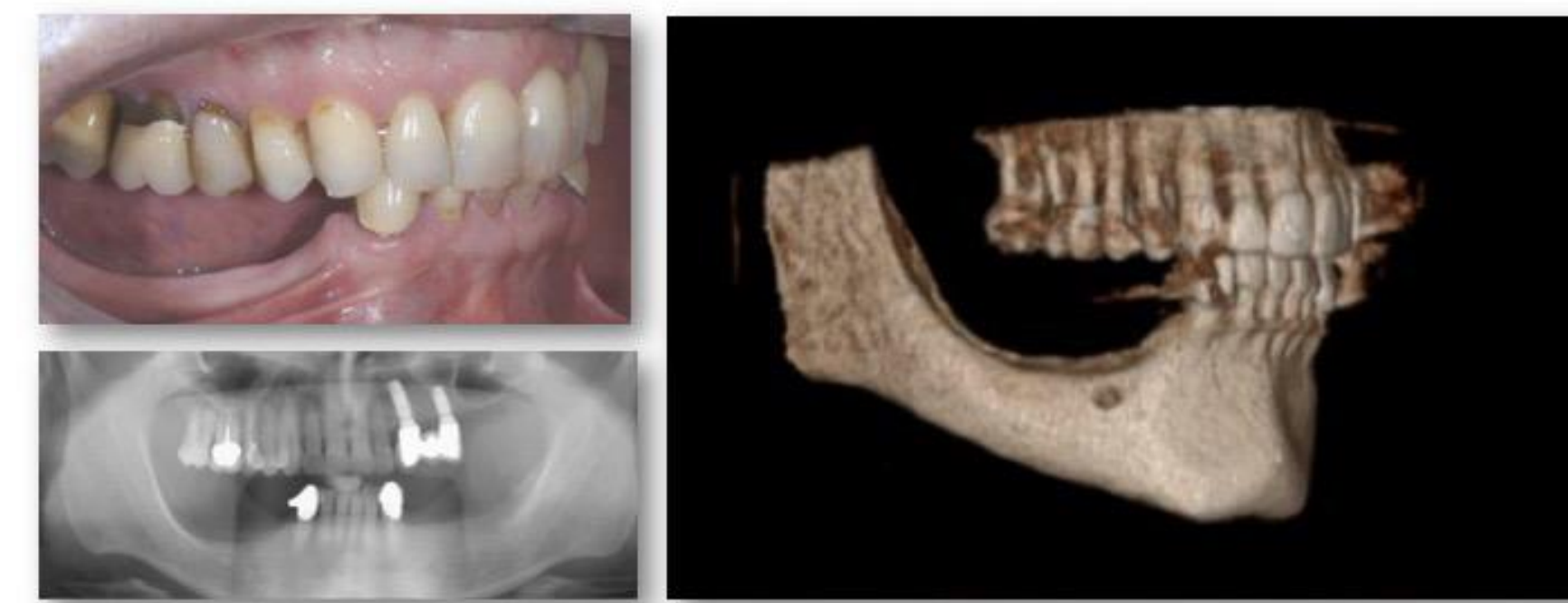MATERIALS AND METHODS

The study was conducted in accordance with ethical guidelines in 3 different centers. All patients requiring bone augmentation for implantoprosthodontic rehabilitation were consecutively treated between 2015 and 2017 by means of titanium plates (Trinon, De Ore srl, Verona, Italy), collagen membranes (Vitala, Osteogenics Biomedical, USA; De Ore srl, Verona, Italy; or Bio-Gide, Geistlich Biomaterials, Vicenza, Italy), and a mixture of autogenous bone and deproteinized bovine bone mineral (DBBM) (Z-core, Osteogenics Biomedical, USA; De Ore srl, Verona, Italy; or Bio-Oss, Geistlich Biomaterials, Vicenza, Italy) (T0). After 6 months of submerged healing, re-entry surgery was accomplished for plate removal and implant placement in the augmented sites (T1). After 3 months (T2), a soft tissue management was accomplished with implant exposure and connective tissue graft, if necessary, before prosthetic restoration (T3). The titanium plate was used as reference tool to measure horizontal and vertical bone gain; moreover, complications rate, class, and type were recorded. Statistical analysis was used to investigate significant correlations between patients, sites, and implant parameters. Patient was used as statistical unit and statistical significance was set at $\alpha=0.05$.

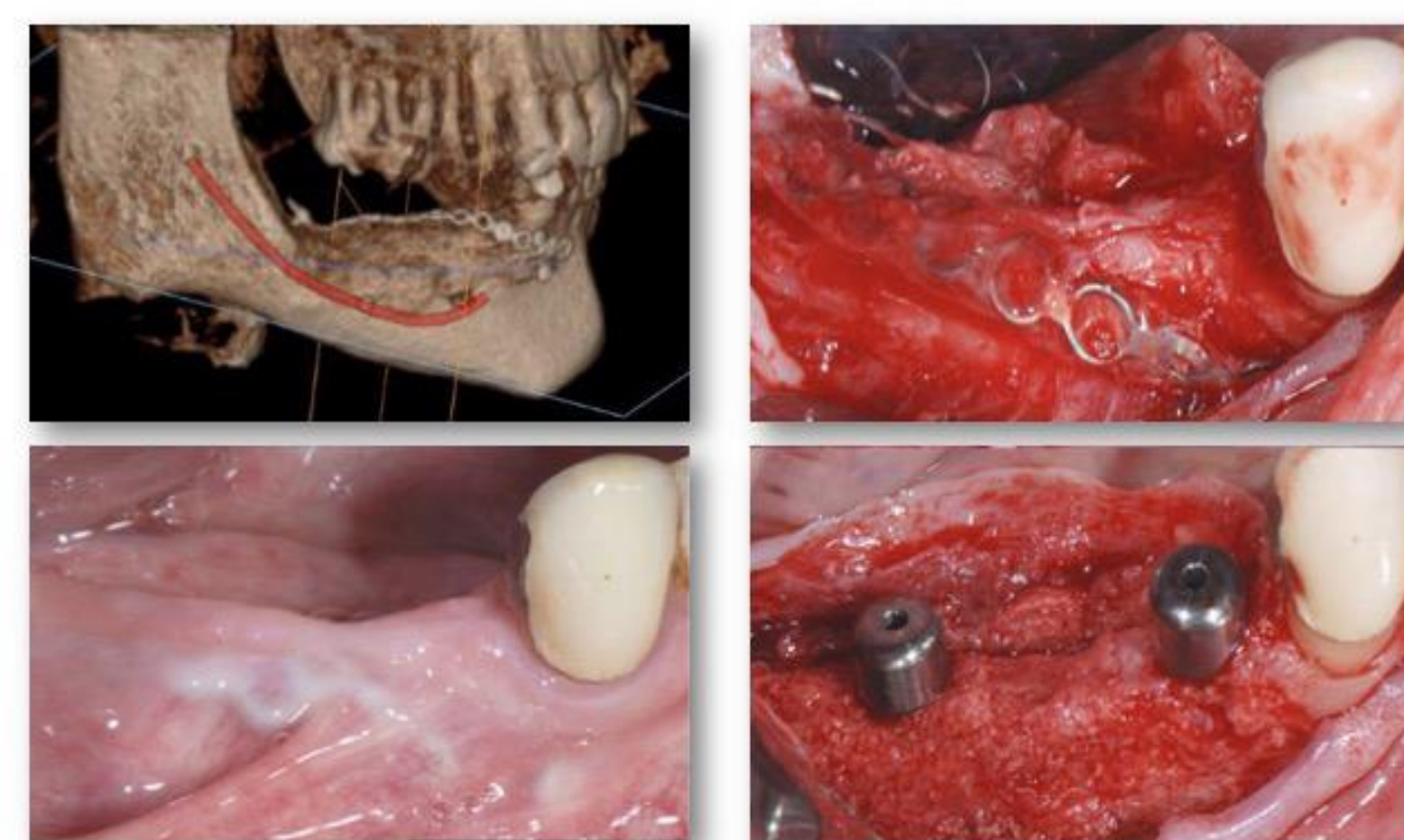
RESULTS

Up to date, 48 sites with horizontal and/or vertical bone defects were treated using the above described surgical approach. In total, 103 implants were placed in augmented sites achieving a primary implant stability greater than 30 Ncm. In all cases with uneventful healing, alveolar ridges increased in height and/or in width (100%) and all implants were placed and osseointegrated as planned. In 12.5% (6/48) of sites, the plates were fully integrated in the newly formed bone; in 20.8% (10/48) integrated more than 50%; in 45.8% (22/48), integrated less than 50%; and in 6.3% (3/48) integrated only in soft tissue. Moreover, 4 plates showed a partial late exposure without suppuration that did not compromise the regeneration. During healing period, complications included 3 localized infections and 2 generalized infections: the first compromised the regeneration only in a localized area, while the latter that were early abscess without exposures that lead a complete failure of bone augmentation procedures. As consequence, overall complications rates was 18.7%, GBR failure rate was 4.2% and success rate of "fence technique" was 95.8%.

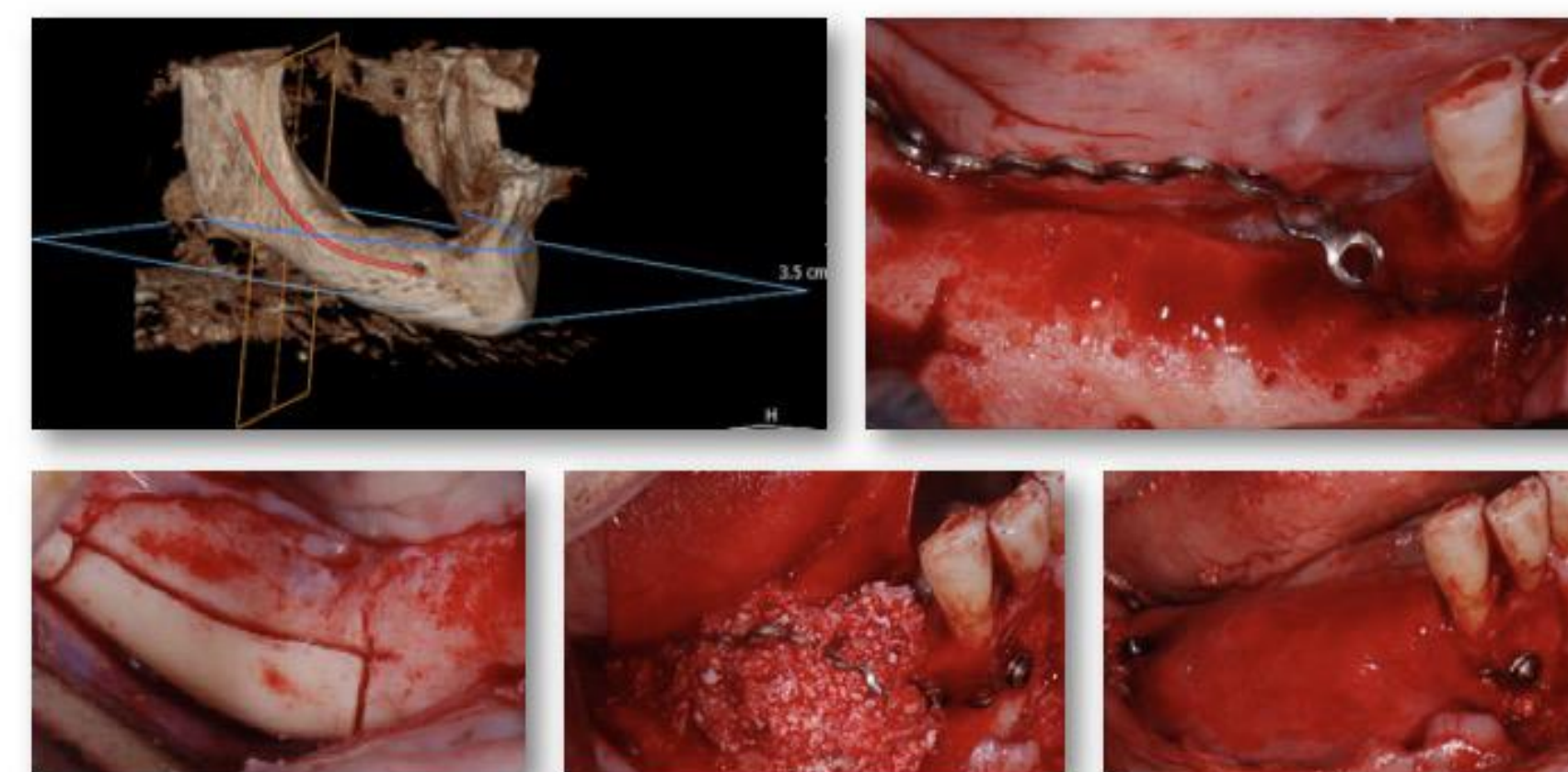
WHICH BONE AUGMENTATION TECHNIQUE DO YOU CHOOSE ?



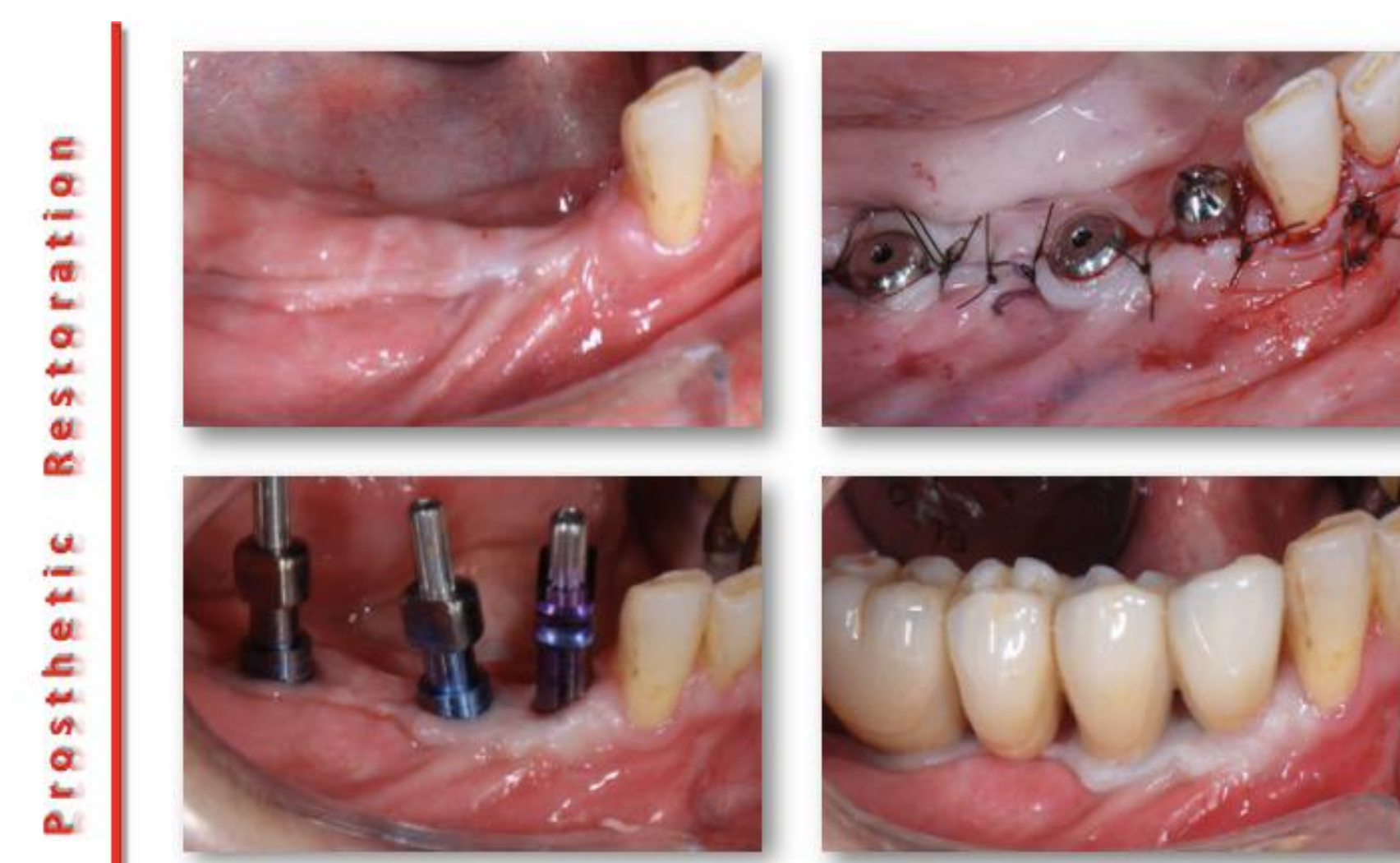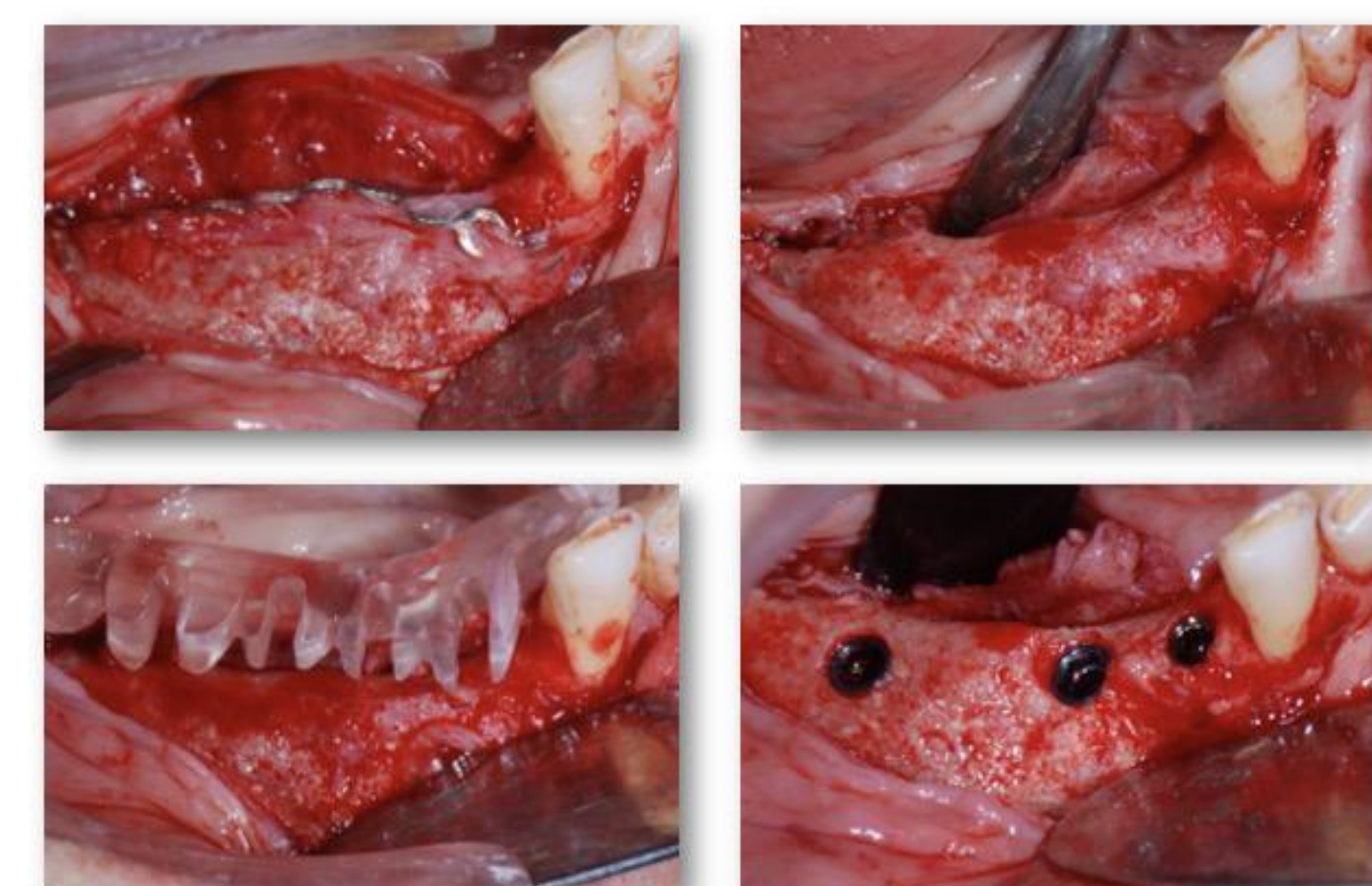
FENCE TECHNIQUE



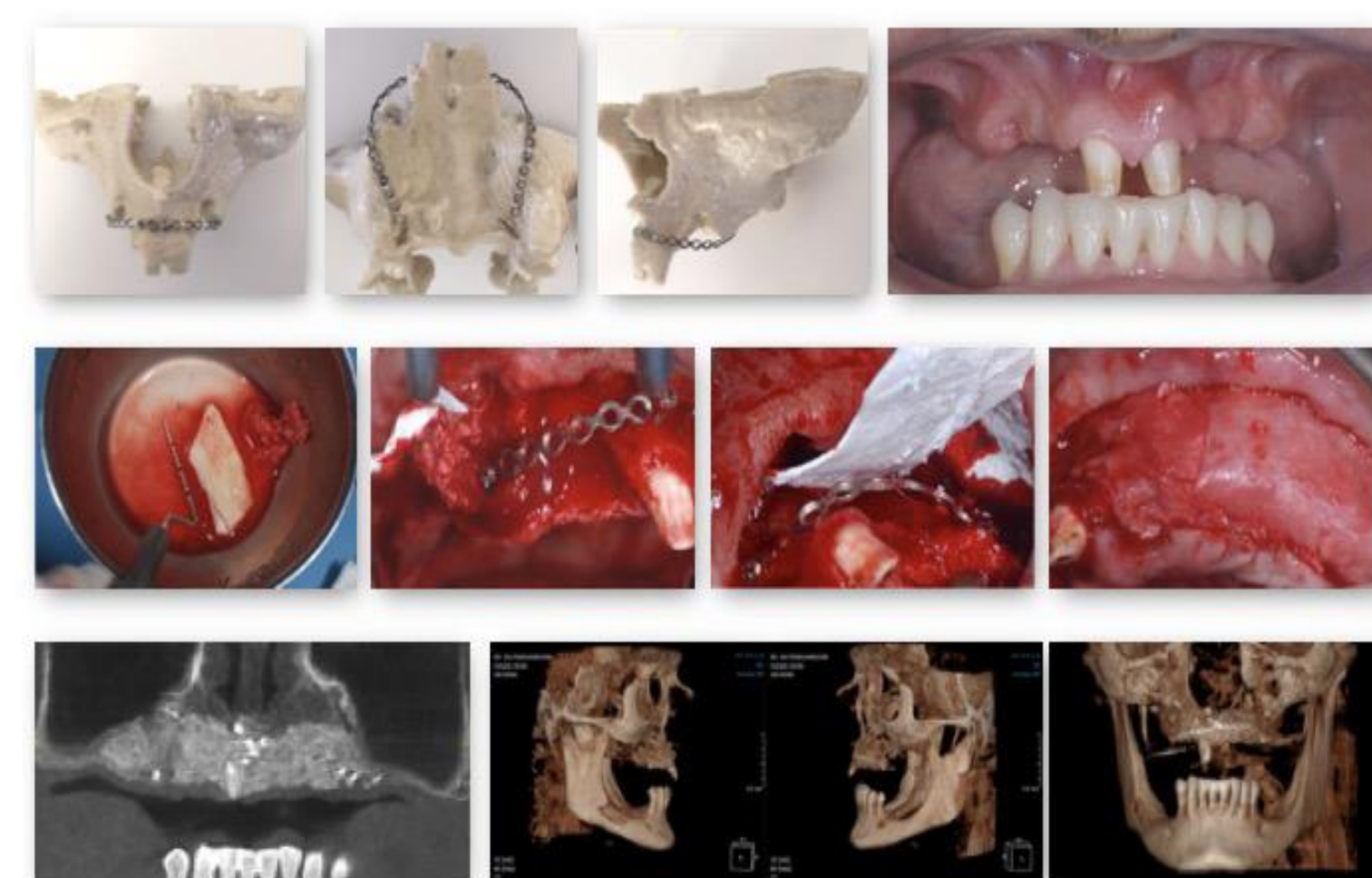
Description of Surgical Protocol



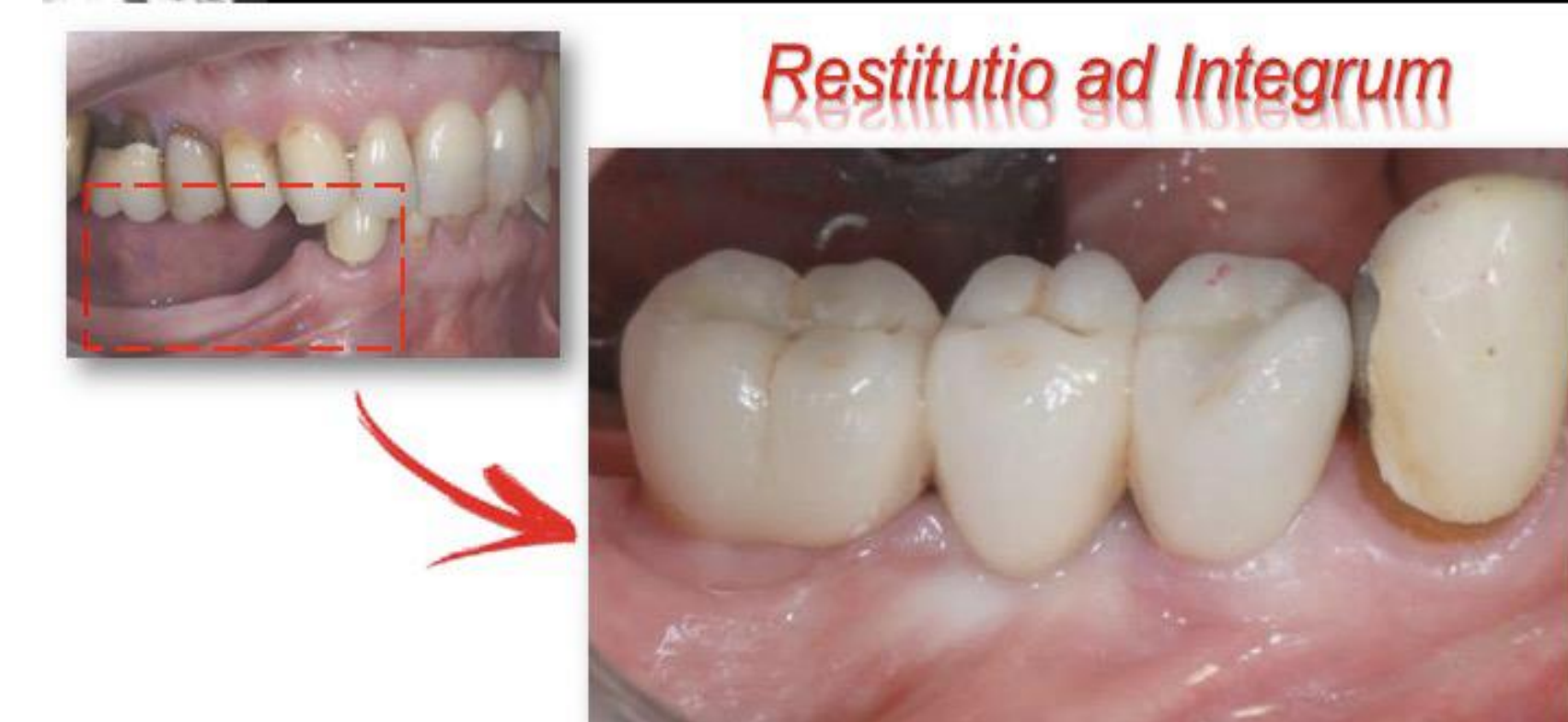Implant Surgery



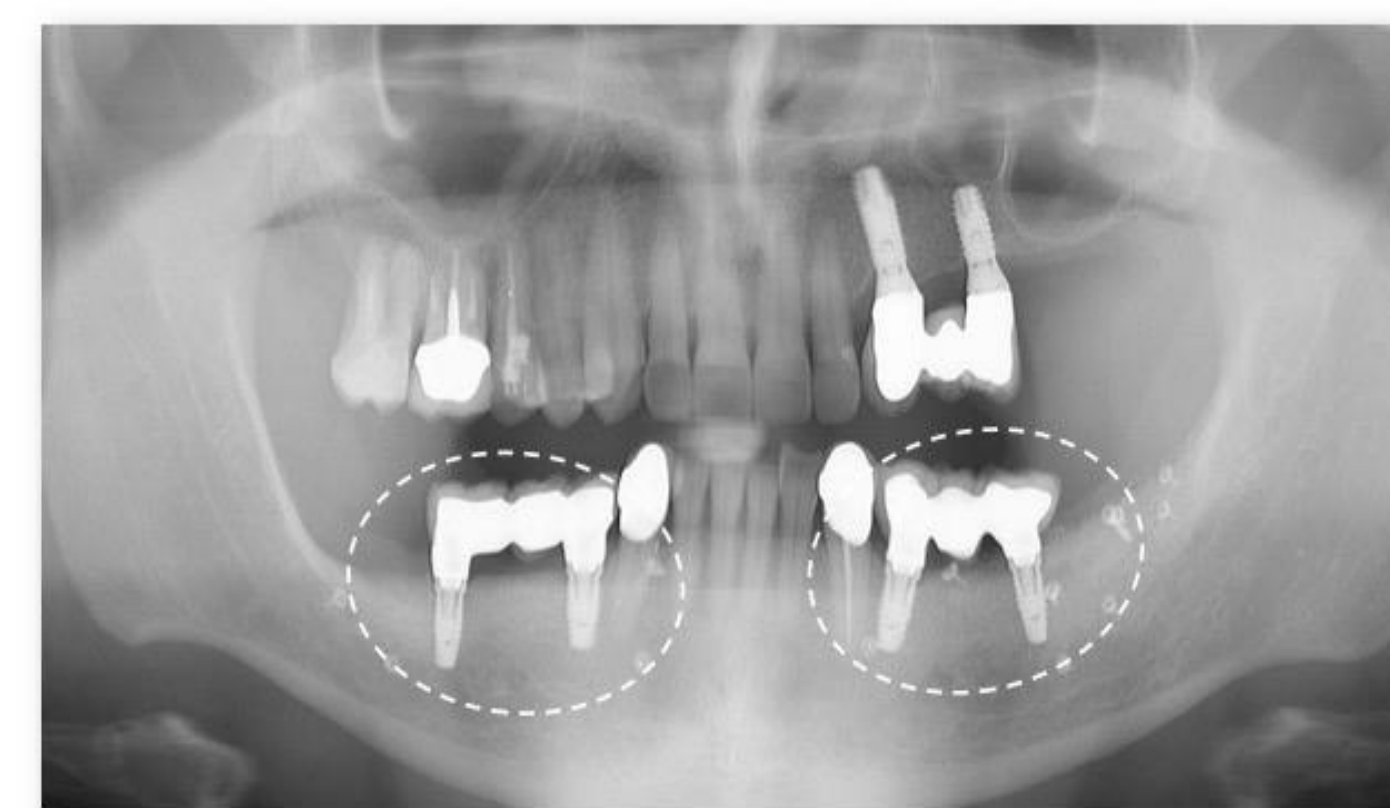
Prosthetic Restoration



WHAT IS THE AIM OF BONE AUGMENTATION ?



STABILITY OF REGENERATED BONE



CONCLUSIONS

The results of this study showed that "Fence Technique" can be considered a reliable and predictable approach for GBR with resorbable membrane for both horizontal and vertical bone defects. Complications can be divided in minor and major ones: the first did not affect the regeneration; the latter lead to a complete failure. The newly-formed bone using resorbable membranes was able to stabilize and osseointegrate implants placed with a staged approach.

References

- Merli M, Moscatelli M, Mazzoni A, Mazzoni S, Pagliaro U, Breschi L, Motroni A, Nieri M. Fence technique: guided bone regeneration for extensive three-dimensional augmentation. Int J Periodontics Restorative Dent. 2013 Mar-Apr;33(2):129-36.
- Merli M, Mariotti G, Moscatelli M, Motroni A, Mazzoni A, Mazzoni S, Nieri M. Fence technique for localized three-dimensional bone augmentation: a technical description and case reports. Int J Periodontics Restorative Dent. 2015 Jan-Feb;35(1):57-64.
- Merli M, Moscatelli M, Mariotti G, Rotundo R, Bernardelli F, Nieri M. Bone level variation after vertical ridge augmentation: resorbable barriers versus titanium-reinforced barriers. A 6-year double-blind randomized clinical trial. Int J Oral Maxillofac Implants. 2014 Jul-Aug;29(4):905-13.