

JOEL L. ROSENLICHT, DMD

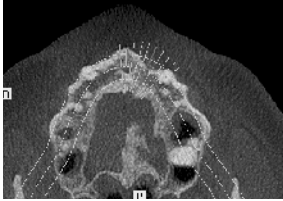


Fig 1a

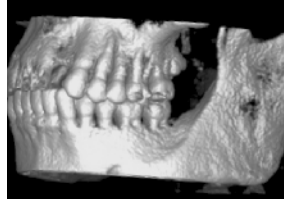


Fig 1b

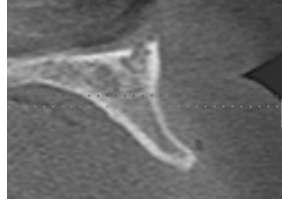


Fig 1c

A 45 year-old male presented with a substantial loss of buccal bone contour and in need of an endosseous implant to replace the maxillary left lateral incisor (Fig 1a-1c).

The alveolar ridge was surgically exposed and decorticated in preparation for bone grafting (Fig 2).

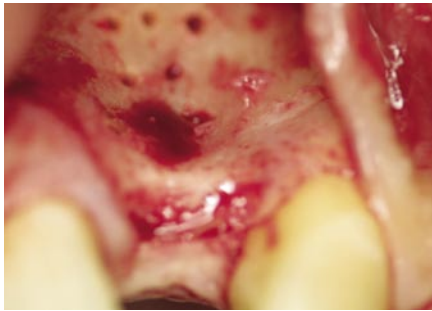

Fig 2

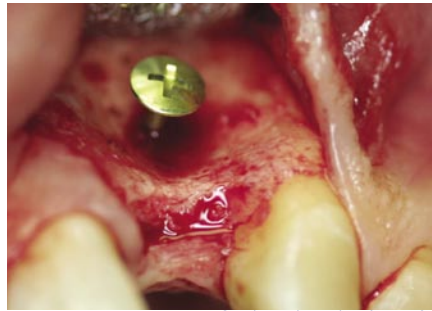


Fig 3

A titanium tenting screw 5.0 mm in length and specifically designed for guided tissue regeneration (JLR Tenting Screw Kit, KLS Martin L.P., Jacksonville, FL) was placed to augment the ridge to a predetermined contour (Fig 3).

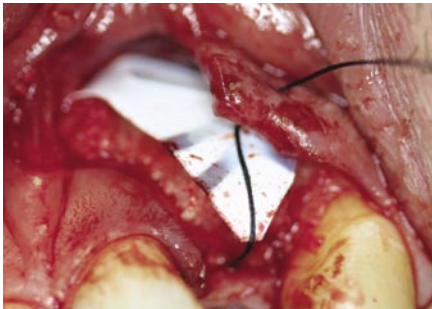


Fig 4a

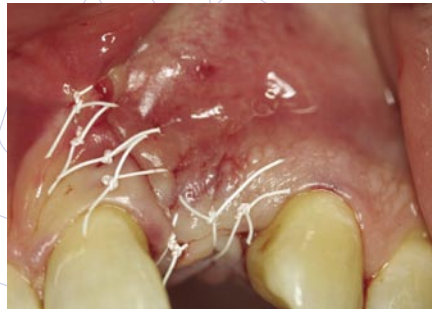

Fig 4b

A composite particulate graft, consisting of demineralized bone putty combined with beta-tricalcium phosphate granules, was then placed and covered with a high-density, titanium-reinforced PTFE membrane (Cytoplast® Ti-250 Posterior Large) and primary closure was achieved using a 3-0 PTFE suture (Cytoplast® PTFE Suture; CS0518) (Fig 4a and 4b).

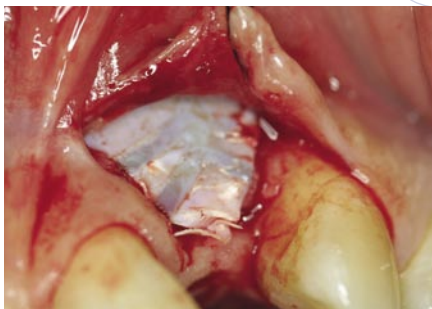


Fig 5a

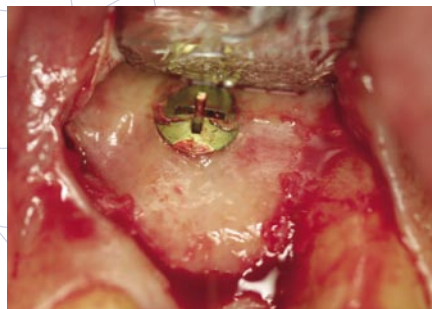


Fig 5b

After 6 months of healing, the augmented site was exposed (Fig 5a) and the membrane was removed (Fig 5b), revealing dense cortical bone under the membrane.

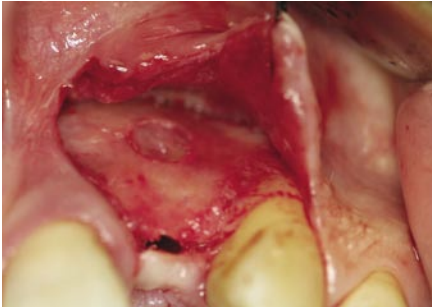


Fig 5c



Fig 5d

Upon removal of the tenting screw (Fig 5c), it is apparent total reconstruction of the ridge contour, up to the height predetermined by the tenting screw and membrane, was achieved.

A CT scan taken prior to the removal of the tenting screw and membrane reveals a substantial increase in width, from 2.9 mm to 8.5 mm, greatly facilitating implant placement in the proper three-dimensional position. (Fig 6a - 6c).

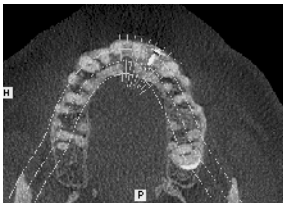


Fig 6a

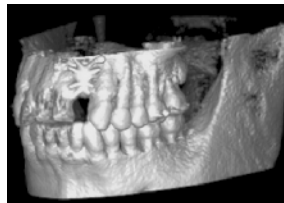


Fig 6b

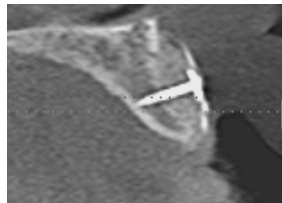


Fig 6c

Cytoplast® is a registered trademark of Osteogenics Biomedical, Inc.

© 2009 Osteogenics Biomedical, Inc.
BBJJ0607

