

EXTRACTION, IMMEDIATE IMPLANT PLACEMENT AND GUIDED BONE REGENERATION USING A FLAPLESS APPROACH

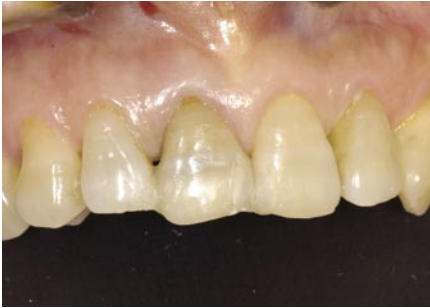

Fig 1

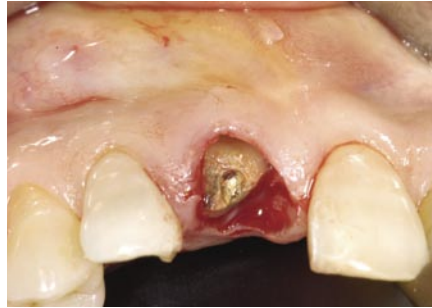

Fig 2

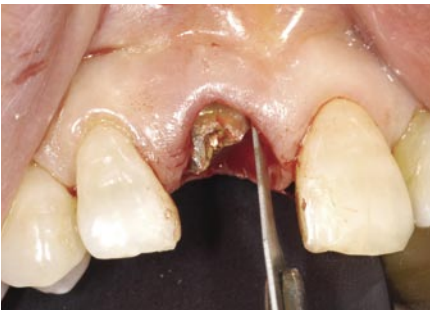

Fig 3

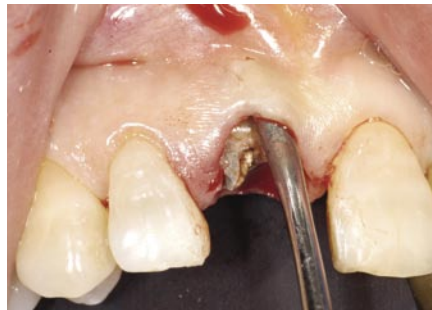

Fig 4

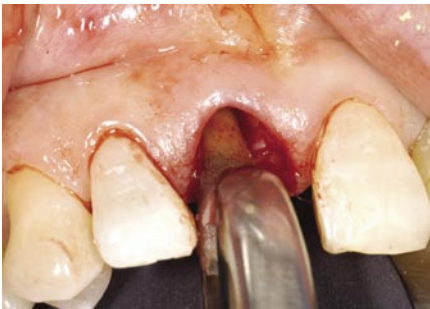

Fig 5

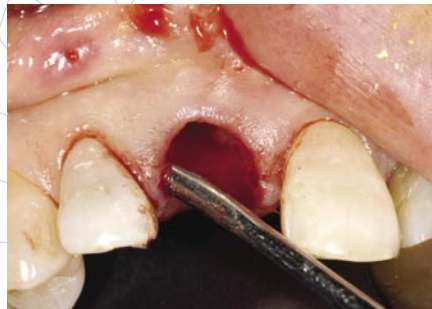

Fig 6

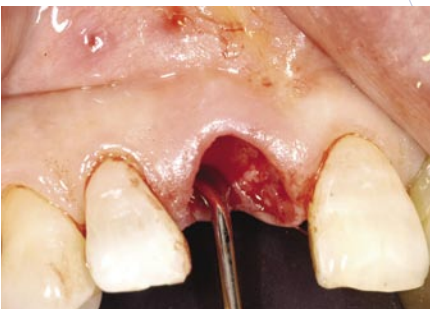

Fig 7

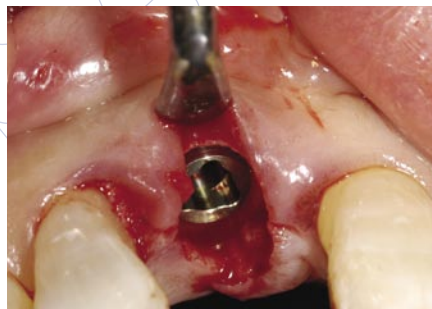

Fig 8

This is a 60 year-old female who presented with a crown-root fracture of a non-vital maxillary right central incisor. The crown was temporarily stabilized with composite resin bonded to the adjacent teeth (Fig 1).

Extraction of the tooth and immediate implant placement was planned. To minimize soft and hard tissue recession, a flapless, minimally invasive extraction technique was employed (Fig 2).

The tooth root was extracted using only an intrasulcular incision. A #15 blade was used to sever the periodontal ligament and create space for root luxation and elevation (Fig 3).

Next, a subperiosteal pocket was created on the buccal and palatal aspect of the socket using a micro periosteal elevator (Fig 4).

Following luxation and initial elevation of the root with the micro elevator, the tooth was removed with forceps (Fig 5).

The interdental papillae were carefully undermined and elevated. This can be done with a small periosteal elevator or curette (Fig 6).

All remaining soft tissue was removed from the interior and margins of the socket with a sharp curette (Fig 7).

The implant osteotomy was done in the standard fashion, with the implant being placed against the palatal wall of the socket (Fig 8).

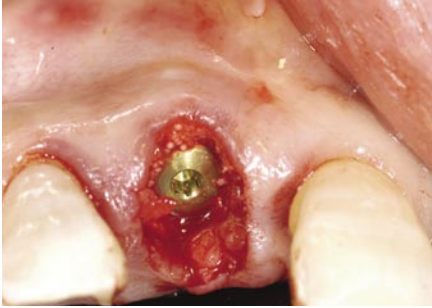

Fig 9

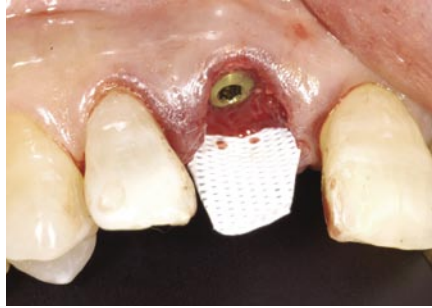


Fig 10

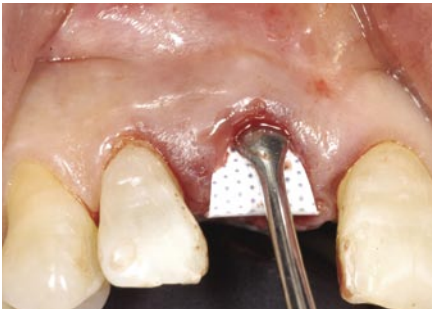

Fig 11

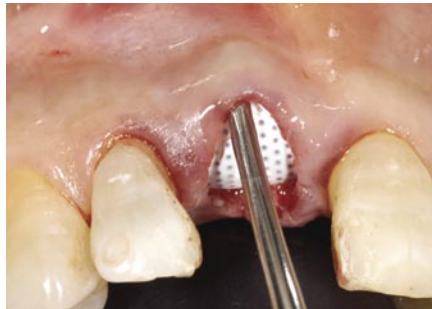

Fig 12

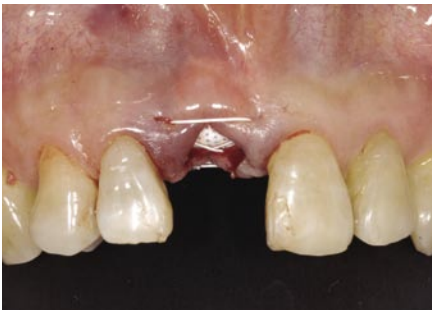

Fig 13

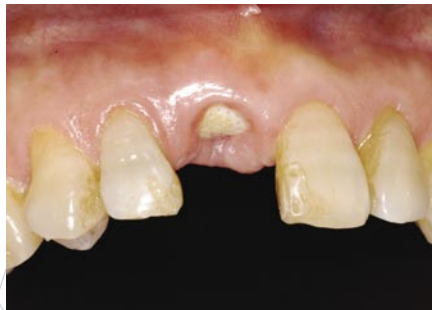

Fig 14

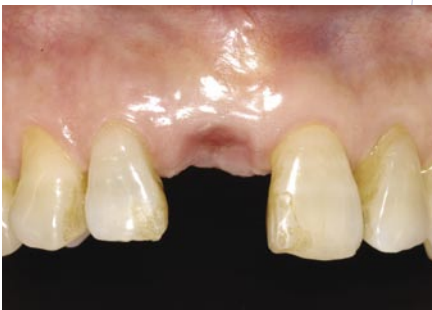

Fig 15

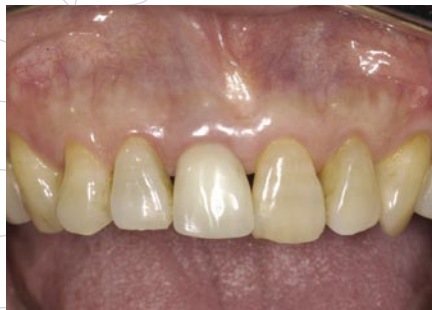

Fig 16

The gap between the facial aspect of the implant and the buccal wall was filled with a combination of autogenous bone chips harvested from the implant osteotomy combined with allograft bone (Fig 9).

A textured, high-density PTFE barrier membrane (Cytoplast® TXT-200) is placed. The membrane is trimmed, then placed into the superiosteal pocket on the palatal aspect (Fig 10).

The membrane is then tucked under the facial flap (Fig 11).

Next, the membrane is tucked under the interdental papillae, taking care to keep the edge of the material a minimum of 1.0 mm away from adjacent tooth roots (Fig 12).

A single 3-0 suture (Cytoplast® PTFE Suture; CS0518) is placed to further stabilize the membrane. The membrane is intentionally left exposed, as primary closure is not required in this technique (Fig 13).

Figure 14 shows the surgical site at 3 weeks. The exposed membrane is easily removed by grasping with a tissue forceps. Topical anesthesia may be used, but local anesthesia is not necessary.

The site at 6 weeks after implant placement (three weeks after membrane removal), reveals keratinized mucosa forming across the former extraction site (Fig 15).

Figure 16 shows the clinical view following placement of the implant abutment and acrylic provisional restoration.

SUMMARY

The flapless technique described provides a minimally invasive approach to extraction with socket grafting or immediate implant placement. Because the interdental papilla remains intact, there is less disruption of blood supply. As a result, there is a greater potential for maintenance of soft tissue volume. In addition, the use of a dense PTFE membrane improves the predictability of immediate implant placement, excluding the requirement for primary closure and resultant disruption of soft tissue architecture.

Cytoplast® is a registered trademark of Osteogenics Biomedical, Inc.

© 2008 Osteogenics Biomedical, Inc.
BBFY0607