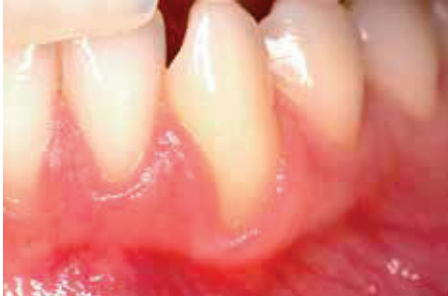

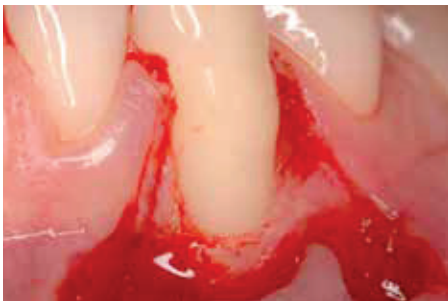TREATMENT OF A GINGIVAL RECESSION

CLINICAL CASE PROVIDED BY PROF ANDREA PILLONI, ROME, ITALY



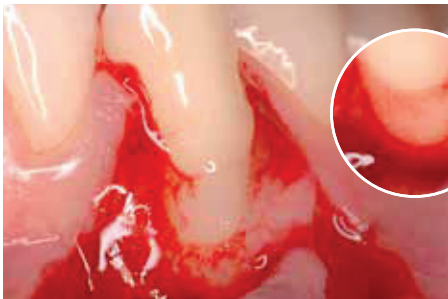
PRE-OPERATIVE

A recession defect of Miller Class II was observed at the lower right canine despite the patient's good dental hygiene and regular dental treatment.

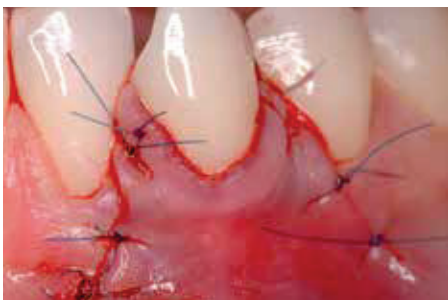

SURGERY

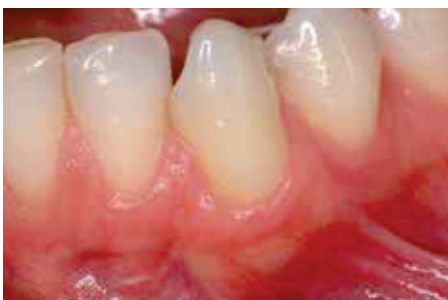The recession was treated surgically. After flap preparation, the root surface was carefully cleaned.



HYADENT BG was applied on to the root surface and incision areas of the soft tissue to support periodontal regeneration and fast wound healing (large image). HYADENT BG mixes well with the blood, which is essential for the clinical efficacy of hyaluronic acid (small image).



The wound was closed with a Coronally Advanced Flap (CAF).



1 YEAR POST-OPERATIVE

The recession remains well covered with healthy soft tissue.