



## A surgical approach for maxillary sinus augmentation and simultaneous implants: a technical note.

**Dr. Valentina Zurlo\***, Cinquegrana Carla, Cucchi Alessandro

\* valentina1686@icloud.com - University of Bologna, Italy



The aim of this report is to describe a surgical approach to immediately stabilize implants with use of titanium mesh (Ti-mesh) and to improve healing process with plasma rich in growth factors (PRGF). If bone height in implant site is less than 3 mm, simultaneous implant placement was not recommended. After radiographic evaluation (OPG, X-ray, CBCT), a lateral window osteotomy and a maxillary sinus lift were realized. Implant sites preparation, biomaterial grafting (autogenous bone, Equimatrix, and PRGF), and implant placement were accomplished. Finally, Ti-mesh (MT-20-46 DeOre) fixation/stabilization and PRGF membrane coverage were the last steps. Bone tissue and soft tissue healing was observed with clinical and radiographic evaluations.

Functional loading was applied 9 months after surgery.

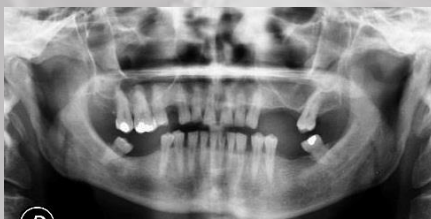

Fig.1 - Pre Operative OPG

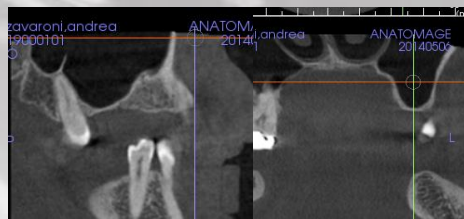


Fig.2 - CBCT scans - lateral and frontal views

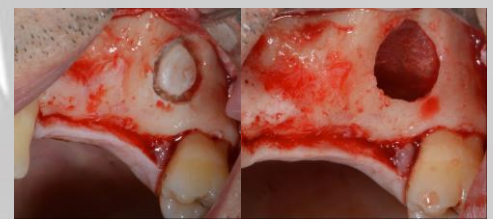

Fig.3 - Lateral window maxillary sinus lift

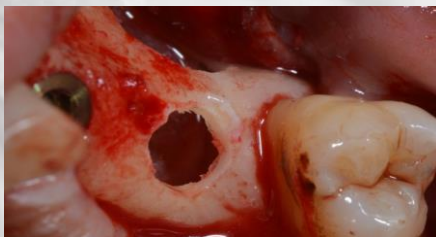

Fig.4 - 1-mm cortical bone thickness

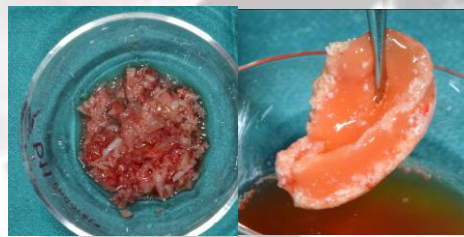


Fig.5 - Autogenous + Equimatrix + PRGF

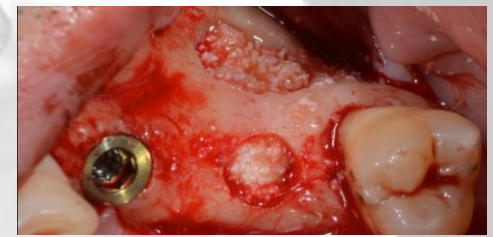

Fig.6 - Bone graft placement

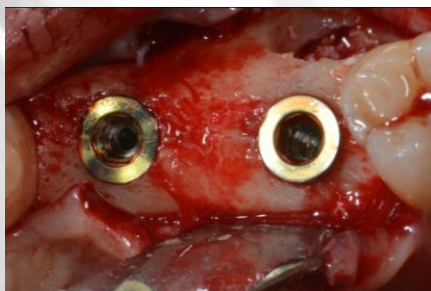

Fig.7 - Smooth 1-mm collar implants

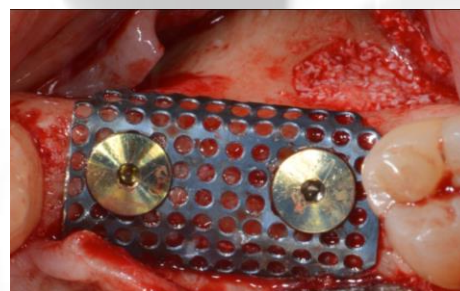


Fig.8 - 0.2-mm thickness Ti-mesh (MT-20-46 DeOre)

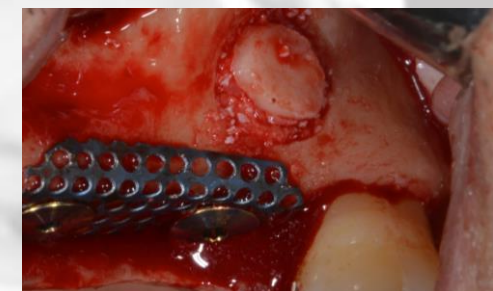


Fig.9 - Lateral window replacement

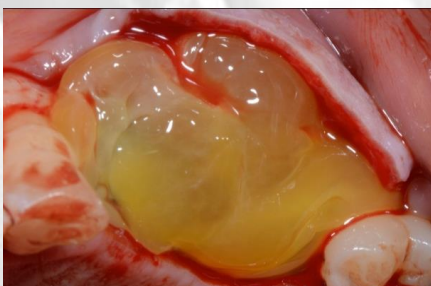


Fig.10 - PRGF coverage for soft tissue healing

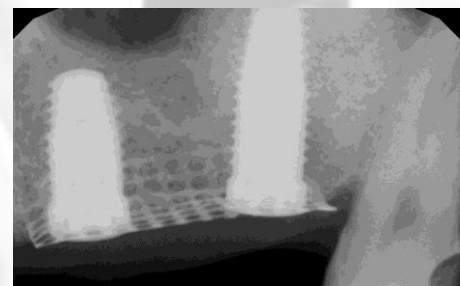


Fig.11 - 6-month healing X-ray

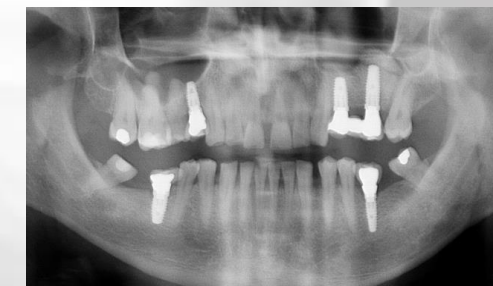

Fig.12 - Definitive restoration OPG

Favourable outcome can be obtained using (i) a Ti-mesh to stabilize implants placed in grafted sinus in order to enhance primary stability, because rigid fixations permitted to avoid micromovements, and (ii) PRGF to give a support to cellular adhesion and bone formation, fastening the healing of bone and soft tissue.